

HYDATID DISEASE OF THE SPLEEN

QURRATULAIN HYDER, *UZMA MIRZA, **DANYAL RASHEED

*Gastroenterology Unit, Pakistan Institute of Medical Sciences (PIMS), Islamabad, Pakistan.

**Combined Military Hospital, Rawalpindi.

Ecchinococcosis usually presents as cystic lesions in the liver and lungs. The involvement of spleen, heart, brain, bone marrow and peritoneum is relatively uncommon (Franquet, 1990). Splenic disease occurs in 2% of cases (Beggs 1985 & Bhatnagar et al., 1994). We report a case of splenic hydatidosis as cause of splenomegaly and left upper abdominal mass, irrespective of serology further supporting the view that unlike medical treatment for visceral ecchinococcosis, surgery ensures eradication of the disease.

Keywords: *Ecchinococcosis; Splenomegaly*

Introduction

Ecchinococcosis (hydatid disease) usually presents as cystic lesions in the liver or lung. The involvement of spleen, heart, brain, bone marrow and peritoneum is relatively uncommon (Franquet et al., 1990). Splenic hydatid cyst occurs in 2%

of all human infestations of *Ecchinococcus* (Beggs, 1985 & Bhatnagar et al., 1994). We present here a case of splenic hydatidosis as an infrequent site of involvement and a rare cause of splenomegaly or mass in the left upper abdomen.

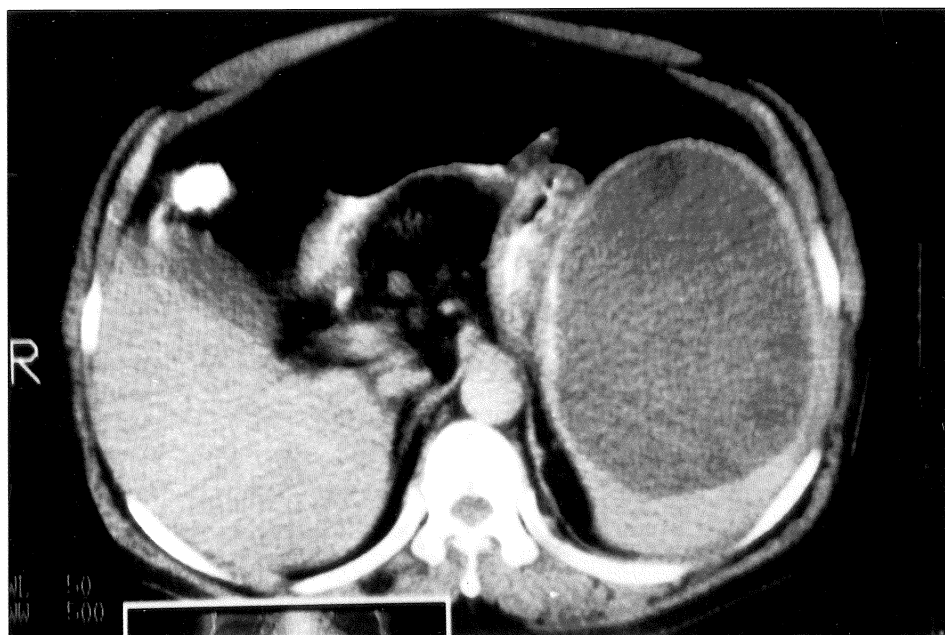


Fig.1. CT-scan showing a large intrasplenic hydatid cyst with clearly defined daughter cysts on the periphery

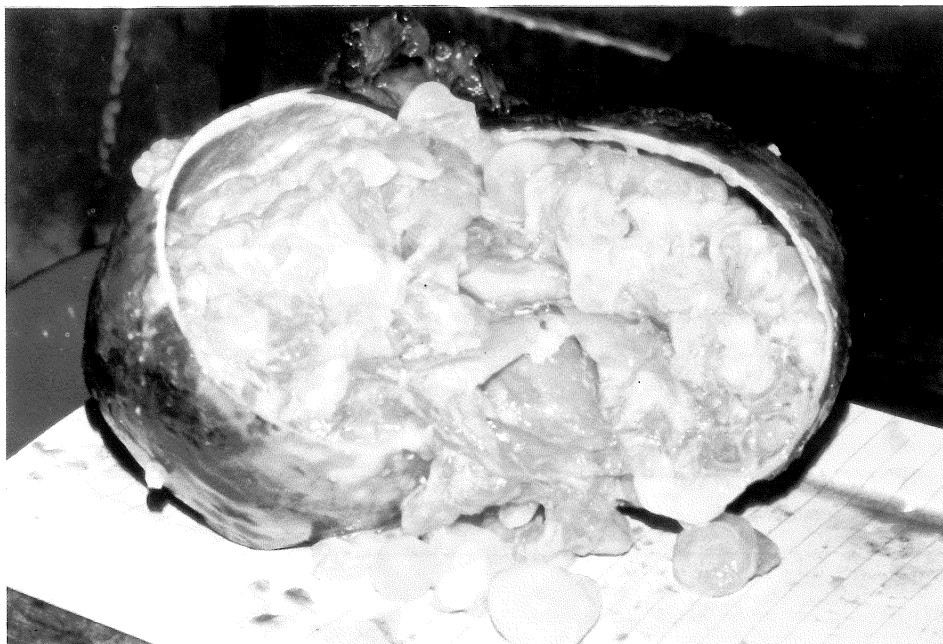

Fig.2. Hydatid cyst showing multiple daughter cysts on excision

Case Report

A fifty year old male sanitary worker presented to us with six months history of mild dragging pain in the left hypochondrium. It increased on standing and coughing and had no relation with meals. There were no urinary, respiratory or bowel symptoms. He gave history of left sided nephrectomy for nephrolithiasis. He was HBsAg positive following recovery from a febrile illness two years ago. The patient was apparently well preserved, normotensive, anicteric and afebrile subject with no stigmata of chronic liver disease. Abdominal examination revealed a non-tender, firm mass in the left hypochondrium. It could be dipped easily for insinuation of fingers beneath the subcostal margin. Other systems were normal clinically. Blood counts, renal and liver function tests, serum electrolytes and chest X-ray were unremarkable. Abdominal ultrasound showed a large mass, measuring 14.4x10 cm located in the spleen. Two cystic lesions were also present in the right kidney. Computed axial

tomography confirmed cystic nature and intrasplenic nature of the lesion (Fig. 1). Indirect haemagglutination test for hydatid disease was negative. Preoperative upper and lower gastrointestinal endoscopy was normal. Splenectomy was performed in December, 1996. The spleen contained a large cyst, surrounded by thin rim of splenic tissue (Fig. 2). Intraoperative diagnosis of hydatid disease of the spleen was later confirmed on microscopy. The patient was given pneumovax and benzylpenicillin postoperatively.

Results and Discussion

Our patient was largely asymptomatic for several years until the intrasplenic cyst was large enough to present as a mass, causing drag in the left hypochondrium. *E. granulosus* presents similarly as sharply circumscribed cystic lesions, often detected up incidentally on x-ray and sonography. Right hypochondrial pain (63%) and mass (48%) are the

commonest modes of presentation (Yidmaz et al., 1990). Hydatid disease remains the commonest cause of liver cysts, especially in endemic areas. The splenic involvement is fairly uncommon (Bhatnagar et al., 1994; Beggs, 1985). *E. vogeli* forms polycystic lesions (Meneghelli et al., 1992) whereas solid lesions of *E. multilocularis* mimic neoplasm (Wang, 1986 & Cosgrove, 1985). Sonography defines cystic nature of hydatid lesions better than computed axial tomography. It has diagnostic sensitivity of 89-100% especially in hepatic hydatidosis (Xynos et al., 1991) having typical features such as small and more uniform loculations and absence of mural cysts, unlike biliary cystadenomas (Wang, 1986 & Cosgrove, 1985). However, the opposite was true in our patient (Bennani et al., 1995). Since the fingers could be easily insinuated beneath subcostal margin, the sonologist raised suspicion of a colonic or pancreatic mass. This necessitated endoscopic evaluation. Hydatid serology was advised only after computed axial tomography showed a large intrasplenic cyst, with daughter cysts on its margins (Figs 1,2). Indirect haemagglutination test has 84% sensitivity. It was negative in our patient and there was no eosinophilia. Serologic testing with antigens Em2 and Ag11/13-10, and DNA probes for hybridization have improved diagnostic accuracy (Gottstein, 1992). Higher levels of tumour associated antigen-CA-19-9 may also be found in hydatid disease (Thomas et al., 1992). Preoperative diagnosis is important in preventing intraoperative spillage of highly antigenic cyst fluid (Hyder et al., 1995). Fine needle aspiration of the cyst with a Chiba needle has been successfully employed in pulmonary hydatids (Ingram et al., 1991). Surgery remains the treatment of choice. Its success depends upon size and anatomic location of the cyst, associated complications such as infection, rupture and

fistulization (Bastani et al., 1995, Xynos et al., 1992, Yidmaz et al., 1990 & Behrns et al., 1991). Hydatid disease carries 90-97% mortality if untreated (Gottstein, 1992). Splenic cyst in our patient had undergone enormous expansion, covered only by a thin rim of splenic tissue (Fig.1). Hence, splenectomy was preferred to cyst removal (Bhatnagar et al., 1994; Cooper et al., 1984). Such lesions are predisposed to spontaneous or posttraumatic rupture if left in situ. Long term treatment with albendazole, mebendazole or praziquantol may stabilize the disease though not necessarily eradicate it (Munzer, 1991 & Wilson et al., 1992). Hence, we opted for medical treatment with albendazole after successful removal of the cyst. Right renal cysts were not explored for being asymptomatic and in view of previous nephrectomy on the left side. We, however, plan to monitor the size of these cysts and renal function regularly. Our patient has done well despite poor compliance with albendazole, postoperatively. This observation further supports the view that medical treatment of hydatid disease is less significant and not as effective as surgery in eradication of hydatid disease.

Conclusion

Splenic hydatidosis should always be considered in differential diagnosis of splenomegaly and a mass in the left hypochondrium, especially in an endemic area like Pakistan.

References

- Bastani, B., Dendashh, F.: *Mt. Sinai J. Med.* 62, (1) 1995
- Beggs, I.: *Am. J. Radiol.* 145, 639 (1985)
- Behrns, K.E., Van Heerden, J.A.: *Mayo Clin. Proc.* 66, 1193, (1991)
- Bennani, S., Blobarod, A., Benjelloun, S.: *Ann.*

- Urol. Paris 29(3) 150 (1995)
- Bhatnagar, V., Agarwala, S., Mitro, D.K.: J. Pediatr. Surg. 29(12) 1570 (1994)
- Cooper, M. J., Williamson, R.C.N.: Br. J. Surg. 71, 173 (1984)
- Cosgrove, D.O.: Liver and the biliary tree (In) Barnett, E., Morley, P. (Eds) Clinical and diagnostic ultrasound. Blackwell Scientific Publications 1985 pp 374-75
- Franquet, T., Montes, M., Leucumbersi, F.J.: Am. J. Radiol. 154, 525 (1990)
- Gottetein, B.: Clin. Microbiol. Rev. 5, 548 (1992)
- Hyder, Q.A., Butt, J., Shazla, M.: Pak. Armed Forces Med. J. 45(2) 103 (1995)
- Ingram, E.A., Helikson, M.A.: Diag. Cytopathol. 7, 5270 (1991)
- Meneghelli, D.G., Martinelli, A.Z.: J. Hepatology 14, 203 (1992)
- Munzer, D.: J.Clin. Gastroenterol. 13, 415 (1991)
- Thomas, J.A., Scriven, M.W., et al.: Cancer 70, 1841 (1992)
- Wang, Y. CT-Scan Of The Abdomen. CRC-Press 205-07, 1986
- Wilson, J.F., Rausch, R.L., et al.: Clin. Inf. Dis. 15, 234 (1992)
- Xynos, E., Pechlivanides, G., et al.: H.P.B. Surg. 4, 59 (1991)
- Yidmaz, E., Gokok, N.: Br. J. Clin. Pract. 44, 612 (1990)

Accepted: 28.12.1998